

## TESTIS-OVA IN SPAWNING BLUE TILAPIA, *OREOCHROMIS AUREUS*

B. CLARK AND H. J. GRIER

Department of Biology, University of South Florida, Tampa, Florida 33620  
and State of Florida Department of Natural Resources, St. Petersburg,  
Florida 33701-5095

**ABSTRACT** Hermaphroditism characterized by the presence of oocytes in the testes is described in the blue tilapia, *Oreochromis aureus*, for the first time. Testis-ova were observed in three of 24 spawning males exhibiting otherwise normal male morphology. The testis-ova appeared non-vitellogenic and lacked a follicle cell layer. It is speculated that the testis-ova did not become vitellogenic due to their association with Sertoli cells and the hormonal environment of the male.

### INTRODUCTION

Intersexuality characterized by oocytes in the testis has been well documented among teleost fishes (Atz 1964, Reinboth 1970, Borg and van der Hurk 1983, Grout 1983). Testis-ova are often found in individuals which exhibit marked intersexuality with gonads divided into distinct ovarian and testicular regions or possessing intermediate secondary sex characters. However, oocytes in otherwise normal males have been reported (Reinboth 1962, Lillelund

1965). In a study of hermaphroditism among "Mbuna" cichlids, Peters (1975) suggested that oocytes in a testis was not conclusive evidence for its being a secondary testis. Furthermore, several specimens examined in that study possessed testis-ova yet exhibited male behavior. During a chromosomal analysis of testicular preparations from the blue tilapia, *Oreochromis aureus*, we observed oocytes in testes of three spawning males. This report offers further evidence for the widespread occurrence of testis-ova among cichlids. To our knowledge, this is the first report of hermaphroditism in *O. aureus*.

Manuscript received December 24, 1984; accepted February 25, 1985.

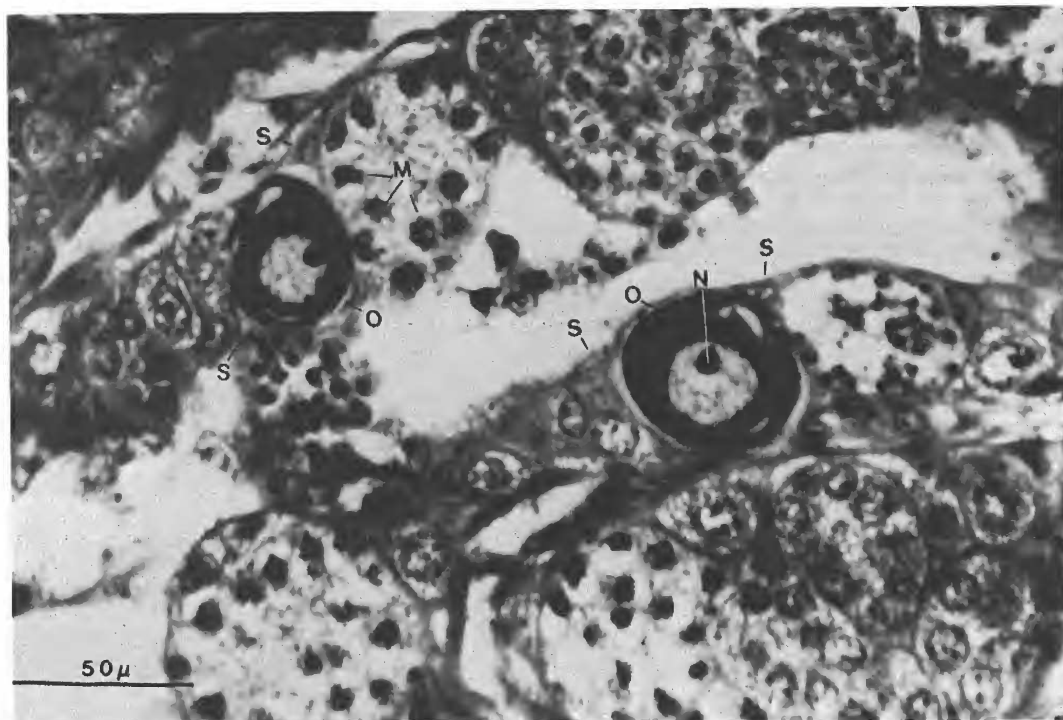


Figure 1. Testis-ova in a blue tilapia, *Oreochromis aureus*. Abbreviations: M = Mitotic spermatogonia, N = Nucleolus, O = Oocytes, S = Sertoli cells.

#### MATERIALS AND METHODS

Twenty-four male blue tilapia were collected by cast netting in irrigation canals of the Hillsborough River (Hillsborough County, Florida) during March 1984. Each specimen received an intraperitoneal injection of 0.1 percent colchicine (Sigma) at a dose of 0.1 ml per 10 grams body weight 6 hours prior to death to accumulate mitotic cells for the chromosomal analysis. Dissected testes were fixed in Bouin's solution, dehydrated through absolute ethanol, and embedded in glycol methacrylate (Polysciences) (Cole and Sykes 1974). For light microscopy, transverse sections 4 microns thick were stained with toluidine blue.

#### RESULTS AND DISCUSSION

All specimens examined were sexually mature and in breeding condition based on coloration and gonad size. Females possessed mature eggs within the ovary. Some were orally incubating eggs or fry.

Histologic examination of the testes revealed active spermatogenesis in all males with numerous meiotic and mitotic figures. In 3 of the 24 males, oocytes occurred among testicular tubules alongside normal spermatogenic

tissue (Figure 1). The oocytes (25 to 75 microns in diameter) were nonvitellogenic and often degenerate. In a few, small nucleoli were associated with the nuclear membrane, characteristic of oocytes in the first meiotic prophase (perinucleolar state). Most of the testis-oocytes, however, possessed a single large nucleolus. A distinct follicle cell layer encompassing the testis-oocytes was not present. Sertoli cell processes retained these oocytes within the spermatogenically active tissue of the testis and apparently prevented them from becoming free within the tubule lumen. We speculate that the oocytes did not become vitellogenic because Sertoli cells cannot function as follicle cells, particularly in the presence of male hormones. The Sertoli cells may also be phagocytosing follicular cells.

Differentiation of oocytes in testicular tissues remains enigmatic. This phenomenon, however, poses basic questions as to mechanisms of germ cell differentiation and illustrates the variable nature of the teleost gonad.

#### ACKNOWLEDGMENT

The authors thank Mr. John Sproukin for cast netting the blue tilapia.

#### REFERENCES CITED

- Atz, J. W. 1964. Intersexuality in fishes. Pages 145-232 in: C. N. Armstrong and A. J. Marshall (eds.), *Intersexuality in vertebrates including man*. Academic Press, New York.
- Borg, B., & R. van der Hurk. 1983. Oocytes in the testes of the three-spined stickleback, *Gasterosteus aculeatus*. *Copeia* 1983: 259-261.
- Cole, M. B., & S. M. Sykes. 1974. Glycol methacrylate in light microscopy: A routine method for embedding and sectioning animal tissues. *Stain Technol.* 49:387-400.
- Grout, D. E. 1983. A case of hermaphroditism in the rainbow smelt, *Osmerus mordax*. *Copeia* 1983:812-813.
- Lillelund, K. 1965. Weitere Untersuchungen über den Hermaphroditismus bei *Osmerus eperlanus* (L.) aus der Elbe. *Z. Morph. Ökol. Tiere* 55:410-424.
- Peters, H. M. 1975. Hermaphroditism in cichlid fishes. Pages 228-235 in: R. Reinboth (ed.), *Intersexuality in the animal kingdom*. Springer-Verlag, New York.
- Reinboth, R. 1962. Morphologische und funktionelle Zweigeschlechtlichkeit bei marinen Teleostiern (Serranidae, Sparidae, Centranchidae, Labridae). *Zool. Jb. Physiol.* 69:405-480.
- \_\_\_\_\_. 1970. Intersexuality in fishes. Pages 515-543 in: G. K. and J. G. Phillips (eds.), *Hormones and the environment*. Cambridge University Press, London and New York.